European Journal of Orthodontics 32 (2010) 575–581
doi:10.1093/ejo/cjp151
Advance Access Publication 17 March 2010

© The Author 2010. Published by Oxford University Press on behalf of the European Orthodontic Society.
All rights reserved. For permissions, please email: journals.permissions@oxfordjournals.org

The incidence of canine transmigration and tooth impaction in a Turkish subpopulation

Ali Murat Aktan*, Sami Kara**, Faruk Akgünlü** and Sıddık Malkoç***
*Department of Oral Diagnosis and Radiology, Faculty of Dentistry, University of Gaziantep, **Departments of Oral Diagnosis and Radiology, Faculty of Dentistry, University of Selcuk, Konya, and ***Department of Orthodontics, University of Inonu, Malatya, Turkey

Correspondence to: Ali Murat Aktan, Gaziantep Üniversitesi, Dişhekimliği Fakültesi, Oral Diagnoz ve Radyoloji A.D. Şahinbey, Gaziantep 27310, Turkey. E-mail: alimurataktan@yahoo.com

SUMMARY The purpose of this study was to determine the incidence of transmigrated maxillary and mandibular canine teeth and also of the other impacted teeth in a Turkish subpopulation.

Five thousand consecutive panoramic radiographs taken of patients who attended the Department of Oral Diagnosis and Radiology, Selcuk University, for routine examination between 2005 and 2007 were examined to identify incidences of transmigrated and impacted teeth. Demographic information of all patients was also recorded. Transmigrations were categorized according to the classification of Mupparapu. The effect of age, gender, and sidedness (left or right side) on the recorded abnormality was evaluated using a *t*-test.

The incidence of transmigrated upper and lower canine teeth was found to be 0.34 per cent [17 patients, 12 females/5 males, with a mean age of 34 years (range 16–76 years)] and 0.14 per cent [7 patients, 4 females/3 males, with a mean age of 37.1 years (range 17–62 years)]. The incidence of tooth impaction was 2.94 per cent [147 patients, 101 females/46 males, with a mean age of 29.7 years (range 15–80 years)]. The most frequently impacted tooth was the upper canine followed by the lower canine, lower second premolar, and upper second premolar. No incidence of maxillary first molar impaction was found. Gender and sidedness did not show a statistical significance on the recorded abnormality ($P = 0.22$ and $P = 0.48$, respectively). However, in the 15–29 year age group, this was statistically different ($P < 0.05$).

The incidence of transmigration of impacted mandibular canine teeth was greater than other teeth. With the increased use of panoramic radiographs, it is inevitable that diagnosis of such anomalies will increase.

Introduction

A tooth that is unerupted more than 1 year after the normal age for eruption is defined as 'retained' (Torres-Lagares *et al.*, 2006). Failure of a tooth to emerge into the dental arch, usually due to either space deficiency or the presence of an entity blocking its path of eruption, results in impaction (Daskalogiannakis, 2000). An impacted tooth occasionally migrates to a location some distance away from the site in which it develops but usually remains within the same side of the arch (Camilleri and Scerri, 2003). When the tooth crosses the midline, this rare phenomenon is known as dental transmigration (Javid, 1985). Although various terminology has been used to describe this condition, the term 'transmigration' is commonly used (Joshi, 2001). While Javid (1985) suggested that a tooth must be classified as transmigrated when more than half of the length of the tooth has passed the midline, Mupparapu (2002) stated that canines were considered transmigrant if the path of eruption had been altered and the tooth had drifted to the opposite side of the mandible with at least half the crown length crossing the midline. Tarsitano *et al.* (1971) also defined it as pre-eruptive migration when a tooth crosses the midline. However, Joshi (2001) considered that not the distance of migration after crossing the midline but the tendency of a canine to cross the barrier of the mandibular midline suture was more important. Moreover, it will depend on the stage of transmigration. Because of the eruption pattern and sequence, canines are prone to impaction and the maxillary canines are affected 20 times more frequently than the mandibular canines (Rohrer, 1929); however, tooth transmigration is seen more frequently in the mandible. While most transmigrated canines are asymptomatic, follicular cystic formation, and chronic infection with fistulization have also been reported (Camilleri and Scerri, 2003). Even though unilateral migration of an impacted tooth (Greenberg and Orlian, 1976; O'Carroll, 1984; Broadway, 1987; Peck, 1998; Rebellato and Schabel, 2003; Shapira and Kuftinec, 2003; Auluck *et al.*, 2006; Buyukkurt *et al.*, 2007; Sumer *et al.*, 2007; Aktan *et al.*, 2008) is more common, bilateral transmigration of mandibular canines has also been observed (Ando *et al.*, 1964; Joshi *et al.*, 1982; Javid, 1985; Kuftinec *et al.*, 1995; Joshi, 2001). Only a few cases of maxillary transmigrated teeth have been reported (Aydin and Yilmaz, 2003; Shapira and Kuftinec, 2005; Aras *et al.*, 2008).

Since impacted or transmigrated teeth are important, especially in terms of orthodontic treatment planning, these teeth must be diagnosed clinically and radiographically. Clinically, over-retention of the primary canine, proclination of the mandibular teeth, and an enlarged symphyseal area are signs of transmigration. To confirm three-dimensionally transmigrated and impacted tooth localization radiographically, dental pantomographs (DPTs), occlusal, periapical, lateral cephalometric (Joshi *et al.*, 1982), and submentovertex projections (Rebellato and Schabel, 2003) can be used. Although surveys related to the incidence of impacted teeth are found in the dental literature (Chu *et al.*, 2003; Yavuz *et al.*, 2007), reports on the incidence of transmigration are rare (Javid, 1985; Zvolanek, 1986; Aydin *et al.*, 2004). An increase in the number of patients with this phenomenon has recently been noted due to the availability of DPTs (Camilleri, 2007). The aim of this study was to determine the incidence of transmigrated maxillary and mandibular canine teeth and of other impacted teeth, in a Turkish subpopulation.

Materials and methods

Five thousand consecutive DPTs of patients who attended the Department of Oral Diagnosis and Radiology, Selcuk University, for routine examination between 2005 and 2007 were examined to identify transmigrated and impacted teeth. Subjects with transmigrated and impacted teeth were identified on DPTs together with periapicals or occlusal and lateral cephalometric radiographs. All radiographs were taken by the same technician on two panoramic systems (Kodak 8000 digital panoramic system; Trophy Radiologies, Croissy-Beaubourg, France and Planmeca Proline CC, Helsinki, Finland) and one peripical system containing two subunits (Kodak RVG 5000; Trophy and Kodak CCX 6510 Digital; Trophy Radiologies).

An intraoral examination was also performed. If the patient was over 16 years and the tooth was not exposed in the oral cavity, it was diagnosed as impacted (Aydin *et al.*, 2004). The tooth was considered transmigrated if the eruption path had been altered and the tooth had drifted to the opposite side of the arch with at least half of the crown length crossing the midline (Mupparapu, 2002). A subject was excluded if transmigration could not be confirmed on an occlusal radiograph.

The classification of Mupparapu (2002) was applied to the transmigrated mandibular canines as follows:

Type 1: Positioned mesioangularly across the midline within the jaw bone, labial, or lingual to the anterior teeth and with the crown portion of the tooth crossing the midline.
Type 2: Horizontally impacted near the inferior border of the mandible below the apices of the incisors.
Type 3: Erupting either mesial or distal to the opposite canine.
Type 4: Horizontally impacted near the inferior border of the mandible below the apices of either the premolars or molars on the opposite side.
Type 5: Positioned vertically in the midline (the long axis of the tooth crossing the midline) irrespective of eruption status.

Statistical evaluation

Using the collected data, the demographic information was calculated for the incidence of canine impaction and transmigration, together with the number and status of missing permanent canines, retained primary canines, and other associated pathologies. All radiographs were assessed by one author (AMA) The incidence of other impacted teeth, except third molars, was calculated as a percentage. The effect of age, gender, and sidedness (left or right side) on the recorded abnormality was evaluated using a *t*-test.

As diagnosis of transmigrated and impacted teeth is an objective assessment and as these teeth are clearly visible on DTPs, it was not considered that a method error study (inter- or intraexaminer reliability) was required.

Results

The number, incidence, age, and gender ratio for impacted and transmigrated canines and for all impacted teeth are shown in Tables 1, 2, and 3, respectively. The incidence of total canine impaction and transmigration was 2.2 (110 subjects, mean age 26.9 years) and 0.48 (24 subjects, mean age 34.91 years) per cent, respectively (Tables 1 and 2). The incidence of all impacted teeth was 2.94 per cent (147 subjects, mean age 29.7 years). The right side (104 subjects) was more frequently affected than the left (71 subjects), and females (101 subjects) were more dominant than males (46 subjects; Table 3). However, the differences were not statistically significant ($P = 0.48$ and $P = 0.22$, respectively). The age range of the patients was 15–80 years (mean 29.73

Table 1 Incidence, age, and gender ratio for canine impaction.

	Subjects	Incidence (%)	No. of teeth	Females	Males	Female/male	Mean age (years)
Maxillary canine impaction	87	1.74	110	78	32	2.44/1	27.5
Mandibular canine impaction	23	0.46	26	18	8	2.25/1	24.3
Total canine impaction	110	2.2	136	95	38	2.5/1	26.9

Table 2 Incidence, age, and gender ratio for canine transmigration. CR, retained primary canine; CE, exfoliated primary canine; AP, associated pathology; nAP, no associated pathology.

	Subjects	Incidence (%)	No. of teeth	Males	Female	Mean age (years)	Right	Left	Bilateral	Impaction	Eruption	CR	CE	AP	nAP
Maxillary canine transmigration	7	0.14	8	3	4	37.14	3	3	1	8	—	1	6	—	7
Mandibular canine transmigration	17	0.34	20	5	12	33.9	9	5	3	20	—	7	10	5	12
Total canine transmigration	24	0.48	28	8	16	34.91	12	8	4	28	—	8	16	5	19

Table 3 Distribution of all impacted teeth in terms of age, gender, and location.

	Subjects	Incidence (%)	No. of teeth	Males	Female	Mean age (years)	Right	Left
Teeth	147	2.94	175	46	101	29.73	104	71
Maxillary canine	87	1.74	110	27	60	27.5	66	44
Mandibular canine	23	0.46	26	6	17	24.3	14	9
Mandibular second premolar	10	0.2	11	6	4	25.3	9	2
Maxillary second premolar	9	0.18	11	4	5	22.7	5	6
Maxillary central incisor	5	0.1	5	1	4	26.6	2	3
Mandibular first premolar	3	0.06	4	1	2	29.2	2	2
Maxillary first premolar	3	0.06	3	1	2	29.6	0	3
Mandibular lateral incisor	2	0.04	2	0	2	59	2	0
Mandibular central incisor	1	0.02	2	0	1	76	1	1
Mandibular second molar	1	0.02	1	0	1	25	1	0
Maxillary lateral incisor	1	0.02	1	0	1	21	1	0
Maxillary second molar	1	0.02	1	0	1	21	0	1
Mandibular first molar	1	0.02	1	0	1	25	1	0
Maxillary first molar	0	0	0	0	0	0	0	0

Table 4 Distribution of total numbers of patients with impacted teeth in the different age groups.

Age groups (years)	Total no. of patients			Total no. of patients with impacted teeth			Total no. of impacted teeth
	Female	Male	Total	Female	Male	Total	
15–19	412	362	774	28	13	41	49
20–29	791	566	1357	29	13	42	57
30–39	580	444	1024	18	8	26	28
40–49	388	445	833	14	5	19	21
50–80	484	528	1012	12	7	19	20
Total	2655	2345	5000	101	46	147	175

years), with those between 15 and 29 years of age having the highest prevalence of tooth impaction, which was statistically significant ($P < 0.05$; Table 4).

Among the 5000 patients for whom DPTs were available, 24 had transmigrated canines in both jaws. The incidence of unilateral and bilateral transmigration was 82.3 and 17.6 per cent, respectively, with the right side affected more often than the left side in both jaws. Eight patients had retained primary canines at the time of diagnosis. Although no dental abnormalities were observed, five patients had pathologies, including cysts or odontomes. None of the patients was aware of the condition and there were no symptoms or signs related to the transmigrated canines. Three patients underwent surgery to extract the transmigrated mandibular canine (Tables 5 and 6).

Seventeen patients (mean age 33.9 years) had a mandibular transmigrated canine. The incidence was 0.34 per cent (Table 2). Among the 17 transmigrated mandibular canines, nine were migrated from the right side, five from the left side, and three were bilateral. According to the classification of Mupparapu (2002), none of the canines was classified as Type 3, four canines (24 per cent) were

Table 5 Clinical and radiographic features of transmigrated mandibular canines in 17 patients. Uni, unilateral; bi, bilateral; I, impacted; CE, exfoliated primary canine.

Subject no.	Type	Side	Primary canine	Eruption status	Associated pathologies	Age (years)	Gender	Uni–bi
1	2	Right	83	I	No	20	F	Uni
2	5	Bilateral	73, 83	I	No	28	F	Bi
3	1	Right	CE	I	No	16	M	Uni
4	1	Right	CE	I	Odontoma*	16	F	Uni
5	1	Right	83	I	Odontoma	17	M	Uni
6	4	Right	83	I	Odontoma	21	M	Uni
7	2	Left	CE	I	No	40	F	Uni
8	2	Right	CE	I	No	76	F	Uni
9	4	Left	73	I	No	24	M	Uni
10	5	Right	83	I	Cyst*	25	F	Uni
11	2	Left	CE	I	No	24	F	Uni
12	5	Bi	CE	I	Cyst*	66	M	Bi
13	1	Left	CE	I	No	24	F	Uni
14	2	Right	CE	I	No	45	F	Uni
15	2	Left	CE	I	No	57	F	Uni
16	2	Bilateral	CE	I	No	40	F	Bi
17	2	Right	83	I	No	39	F	Uni

*Operated.

Table 6 Clinical and radiographic features of transmigrated maxillary canines in seven patients. Uni, unilateral; Bi, bilateral; CE, exfoliated primary canine.

Subject no.	Side	Primary canine	Associated pathologies	Age (years)	Gender	Uni–bi
1	Left	CE	No	46	F	Uni
2	Left	63	No	17	F	Uni
3	Bilateral	CE	No	58	F	Bi
4	Right	CE	No	21	F	Uni
5	Right	CE	No	30	M	Uni
6	Left	CE	No	26	M	Uni
7	Right	CE	No	62	M	Uni

Type 1 (Figure 1a), eight Type 2 (Figure 1b; 46 per cent), two Type 4 (Figure 1c; 12 per cent), and three Type 5 (Figure 1d; 18 per cent; Table 5). Seven patients (mean age 37.1 years) had a maxillary transmigrated canine, an incidence of 0.14 per cent (Table 2). Three canines had migrated from the left side and three from the right, only one canine was found to be bilateral in the midline (Table 6). There were no statistically significant gender and side differences regarding transmigration of teeth ($P = 0.70$). However, mandibular canine transmigration was found significantly more frequent than maxillary transmigration ($P < 0.05$).

Discussion

Previous reports related to transmigrated teeth comprised only maxillary and mandibular canine teeth. In this study, the incidence of impacted and transmigrated canines was investigated together with the incidence of the other impacted teeth. Similar to other studies on the prevalence of impacted teeth (Zvolanek, 1986; Rajic *et al.*, 1996; Chu *et al.*, 2003; Aydin *et al.*, 2004; Aras *et al.*, 2008), the third molars were excluded. In descending order, the tooth types impacted were as follows: maxillary canine, maxillary and mandibular premolar, and mandibular canine. Of the 175 impacted teeth, the most frequent were the maxillary canines, followed by the mandibular canines, maxillary, and mandibular premolars. Aydin *et al.* (2004) found that the incidence of canine impaction was 3.58 per cent, while Yavuz *et al.* (2007) found it to be 1.29 per cent. In the current study, the incidence was 2.2 per cent. Although the investigated subjects may not represent the whole Turkish population, there was no significant variation in the prevalence and distribution of impacted canines and the results were in agreement with findings of Aydin *et al.* (2004) and Yavuz *et al.* (2007) in other Turkish subpopulations.

Javid (1985) found, in a radiographic survey of 1000 students, only one transmigrated canine, while Zvolanek (1986) failed to find any cases in 4000 patients. In another

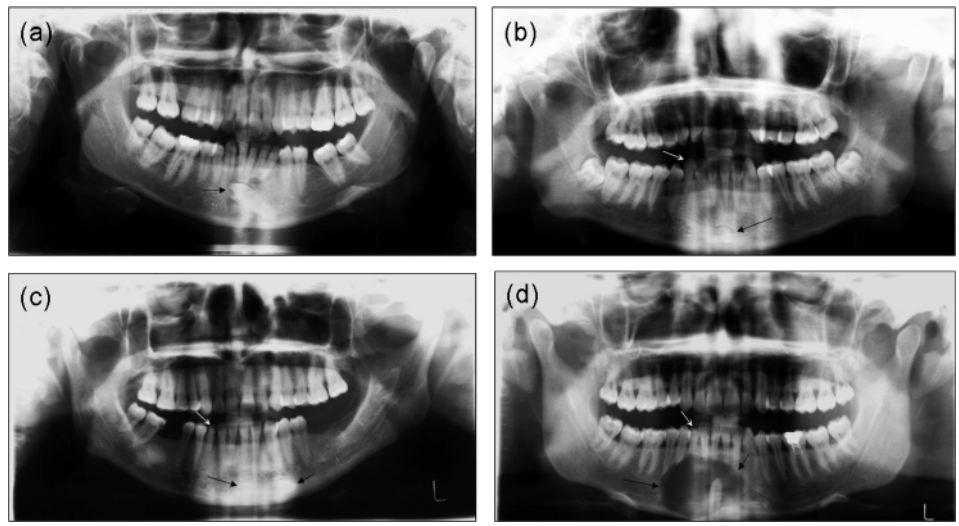

Figure 1 Dental pantomograph showing transmigrated mandibular canines with their classification according to Mupparapu (2002) (a) Type 1: a 24-year-old female with a transmigrated mandibular left canine in a mesioangular position. (b) Type 2: a 20-year-old female with a transmigrated right canine lying horizontally with its crown crossing the midline. (c) Type 4: a 15-year-old girl with a transmigrated right canine lying horizontally with its root across the midline. (d) Type 5: a 39-year-old female with a mandibular right canine in a vertical position surrounded by a dentigerous cyst in the midline. White and black arrows indicate persistent and transmigrated teeth, respectively.

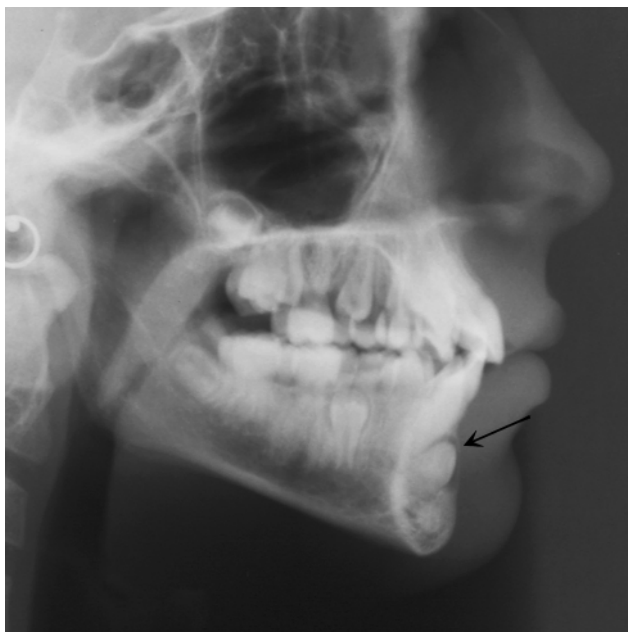

Figure 2 Lateral cephalometric radiograph of a 15-year-old boy with a transmigrated mandibular canine in the labial aspect of the symphyseal region.

report, 14 maxillary and mandibular transmigrated canines were found in 4500 patients (Aydin *et al.*, 2004). Joshi *et al.* (1982) was the first to report the bilateral occurrence of transmigrated canines and later Javid (1985) observed three cases of bilateral occurrence of this abnormality. The findings in the present study are in agreement with the above surveys on the incidence of transmigrated canines.

Figure 3 Type 2: dental pantomograph of a 40-year-old female with bilateral transmigrated mandibular canines lying horizontally.

Rohrer (1929) observed that impacted canines were 20 times more frequent in the maxilla than in the mandible, and Chu *et al.* (2003) reported this ratio to be 6.14. In studies of Turkish patients, this ratio was shown by Aydin *et al.* (2004) to be 7.47 and by Saglam and Tüzüm (2003) 9.62. Although canine impaction occurs more frequently in the maxilla than in the mandible (Rohrer, 1929; Yavuz *et al.*, 2007), impacted maxillary canines had not been observed migrating across the palatal midline suture until the report of Aydin and Yilmaz (2003). The results of the present study revealed a 4-fold difference between the maxilla and mandible. Although this lower frequency cannot be clearly explained compared with the findings of Rohrer (19289), these results indicate that the incidence of canine impaction may vary in different populations. Although the maxillary canines were commonly impacted, the probability for transmigration of mandibular impacted canines was high. When all impacted

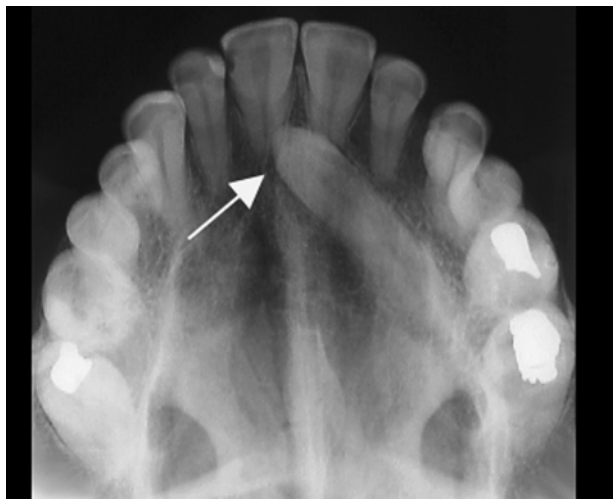

Figure 4 Panoramic radiograph of a 46-year-old male with a left maxillary canine crossing the midline.

Figure 5 Occlusal radiograph of a 46-year-old female with a canine crossing the midpalatal suture confirming the transmigration of the maxillary canine.

mandibular canines were considered, no tooth was found that had migrated distally through bone.

Although a number of factors have been suggested with regard to transmigration, the aetiology and exact mechanism is still unclear (Camilleri and Scerri, 2003). It has been suggested that canine migration is congenital (Peck, 1998). Some possible aetiological factors are: retention or premature loss of primary teeth, crowding, spacing, supernumerary teeth, and an excessive crown length of the mandibular canine (Ando *et al.*, 1964; Shapira and Kuftinec, 2003). Besides tumours and cysts, odontomes may cause malposition of the teeth if they lie in the path of eruption (Ando *et al.*, 1964; Al-Waheidi, 1996; Shapira and Kuftinec, 2003). Nodine (1943) reported that impacted and migrated mandibular canines often do not produce any apparent symptoms, and Ando *et al.* (1964) did not observe symptoms such as pain or oppression of the mandibular nerve due to the transmigration of a canine in their study. Shapira and Kuftinec (2003) stated that this abnormality was usually accompanied by a cyst or odontoma. Al-Waheidi (1996) suggested that transmigrated canines were usually associated with a cystic lesion and that the presence of a cyst at the crown of the canine might facilitate the migration process. Joshi (2001) stated that it was difficult to differentiate whether these pathological conditions were responsible for the transmigration process, or that the pathology occurred after the migration of the canine. In the present study, mandibular transmigrations were associated with odontomes in three subjects and with cysts in two. No transmigrations in the maxilla had any pathological entity. However, all of these pathological cases could not clearly explain the pattern of the transmigration process.

Intraorally, swelling at the buccal or lingual side of the arch and the presence of the primary canine usually indicates the probability of the presence of an impacted or transmigrated tooth. DPT, occlusal, periapical, and submentovertex projections can be used to determine the three-dimensional location of the transmigrated canine (Rebellato and Schabel, 2003). Lateral cephalometric radiographs can also assist in localization of the impacted tooth (Figure 2). Computed tomography (CT) is the gold standard for three-dimensional localization of impacted teeth, although radiation exposure could be an issue. In present study, the records of 5000 consecutive patients were examined retrospectively. DPTs were taken of each patient for routine dental examination, while CTs were obtained only in specific cases, such as implant surgery, tumours, or cysts. Therefore, in this retrospective study, DPTs were used to localize the impacted canines in addition to other records.

While most investigators (Peck, 1998; Mupparapu, 2002; Camilleri and Scerri, 2003; Shapira and Kuftinec, 2003; Camilleri, 2007) reported that the left canine was more often involved than the right and that females tended to have this pathology more frequently than males, Aydin *et al.* (2004) found that males tend to have this condition more frequently than females. In the current study, the female predilection was more dominant and the right side was found to be more frequently affected than the left; however, statistical analysis showed no significant difference with regard to side or gender predilection ($P = 0.48$ and $P = 0.22$). This difference could be explained by the fact that more females than males seek dental treatment, although as yet there is no consensus on the domination of gender predilection (Aydin *et al.*, 2004; Joshi, 2001). In early reports, it was shown that bilateral transmigration was a rare occurrence (Joshi, 2001; Mupparapu, 2002; Camilleri and Scerri, 2003; Aydin *et al.*, 2004). While the classification of Mupparapu (2002) does not include subjects with bilateral transmigration, the classification was easy to apply to the three mandibular bilateral subjects in the present study. Figure 3 shows the bilaterally transmigrated canines classified as Type 2.

Unlike mandibular transmigration, Joshi (2001) believed that there is a barrier, the maxillary midpalatal suture, which prevents a palatally impacted maxillary canine crossing to the opposite side of the arch, however, some recent reports have shown cases of maxillary transmigration (Aydin and Yilmaz, 2003; Shapira and Kuftinec, 2005). The maxillary

transmigrated canines found in the present study were not considered to be fully transmigrated. The crowns of all canines were located in the midpalatal suture. This suggests that the midpalatal suture did not allow the teeth to totally pass to the opposite side (Figures 4 and 5). Although the transmigrated maxillary canines did not show variations in their location or position, classification by Mupparapu (2002) could not be used for maxillary transmigrated teeth.

Treatment options for transmigrated or impacted teeth include surgical removal, transplantation, and surgical exposure with orthodontic alignment (Rebellato and Schabel, 2003). Surgical extraction is more appropriate (Camilleri and Scerri, 2003). For successful orthodontic treatment, a migrated tooth must be detected in the early stages, otherwise treatment will be more complicated. Long-term follow-up, if there are no symptoms, may be an alternative option. In present study, none of the subjects with transmigrated teeth had undergone orthodontic treatment. Only three patients underwent surgery to extract the transmigrated mandibular canines.

Conclusion

According to the current study, except for the canine, no tooth type showed a tendency to transmigrate in the dental arch. The possibility of transmigration of an impacted mandibular canine was greater than for an impacted maxillary canine.

References

Aktan A M, Kara S, Akgunlu F, Isman E, Malkoc S 2008 Unusual cases of the transmigrated mandibular canines: report of 4 cases. European Journal of Dentistry 2: 122–126

Al-Waheidi E M H 1996 Transmigration of unerupted mandibular canines: a literature review and a report of five cases. Quintessence International 27: 27–31

Ando S, Aizawa K, Nakashima T, Sanka Y, Shimbo K, Kiyokawa K 1964 Transmigration process of impacted mandibular cuspid. Journal of Nihon University School of Dentistry 6: 66–71.

Auluck A, Nagpal A, Setty S, Pai K M, Sunny J 2006 Transmigration of impacted mandibular canines—report of 4 cases. Journal of the Canadian Dental Association 72: 249–252

Aydin U, Yilmaz H H 2003 Transmigration of impacted canines. Dentomaxillofacial Radiology 32: 198–200

Aydin U, Yilmaz H H, Yildirim D 2004 Incidence of canine impaction and transmigration in a patient population. Dentomaxillofacial Radiology 33: 164–169

Aras M H, Buyukkurt M C, Yolcu U, Ertas U, Dayi E 2008 Transmigrant maxillary canines. Oral Surgery, Oral Medicine, Oral Pathology and Endodontics 105: 48–52

Broadway R T 1987 A misplaced mandibular permanent canine. British Dental Journal 163: 357–358

Buyukkurt M C, Aras M H, Caglaroglu M, Gungormus M 2007 Transmigrant mandibular canines. Journal of Oral Maxillofacial Surgery 65: 2025–2029

Camilleri S 2007 Double transmigration and hyperdontia. Angle Orthodontist 77: 742–744

Camilleri S, Scerri E 2003 Transmigration of mandibular canines—a review of the literature and a report of five cases. Angle Orthodontist 73: 753–762

Chu F C S, Li T K L, Lui V K B, Newsome P R H, Chow R L K, Cheung L K 2003 Prevalence of impacted teeth and associated pathologies—a radiographic study of the Hong Kong Chinese population. Hong Kong Medical Journal 9: 158–163

Daskalogiannakis J 2000 Multilingual glossary of orthodontic terms. Quintessence Publishing Co, Inc., Berlin, p. 142

Greenberg S N, Orlian A I 1976 Ectopic movement of an unerupted mandibular canine. Journal of the American Dental Association 93: 125–128

Javid B 1985 Transmigration of impacted mandibular cuspids. International Journal of Oral Surgery 14: 547–549

Joshi M R 2001 Transmigrant mandibular canines: a record of 28 cases and a retrospective review of the literature. Angle Orthodontist 71: 12–22

Joshi M R, Daruwala N R, Ahuja H C 1982 Bilateral transmigration of mandibular canines. British Journal of Orthodontics 9: 57–58

Kuftinec M M, Shapira Y, Nahlieli O 1995 A case report. Bilateral transmigration of impacted mandibular canines. Journal of the American Dental Association 126: 1022–1024

Mupparapu M 2002 Patterns of intra-osseos transmigration and ectopic eruption of mandibular canines: review of literature and report of nine additional cases. Dentomaxillofacial Radiology 31: 355–360

Nodine A 1943 Abberant teeth, their history, causes and treatment. Dental Items of Interest 65: 440–451

O'Carroll M K 1984 Transmigration of the mandibular right canine with development of odontoma in its place. Oral Surgery, Oral Medicine, and Oral Pathology 57: 349

Peck S 1998 On the phenomenon of intraosseous migration of nonerupting teeth. American Journal of Orthodontics and Dentofacial Orthopedics 113: 515–517

Rajic S, Muretic Z, Percac S 1996 Impacted canine in a prehistoric skull. Angle Orthodontist 66: 477–480

Rebellato J, Schabel B 2003 Treatment of a patient with an impacted transmigrant mandibular canine and a palatally impacted maxillary canine. Angle Orthodontist 73: 328–336

Rohrer A 1929 Displaced and impacted canines. International Journal of Orthodontics and Oral Surgery 15: 1002–1004

Saglam A A, Tüzüm M S 2003 Clinical and radiologic investigation of the incidence, complications, and suitable removal times for fully impacted teeth in the Turkish population. Quintessence International 34: 53–59

Shapira Y, Kuftinec M M 2003 Intrabony migration of impacted teeth. Angle Orthodontist 73: 738–743

Shapira Y, Kuftinec M M 2005 Unusual intraosseous transmigration of a palatally impacted canine. American Journal of Orthodontics and Dentofacial Orthopedics 127: 360–363

Sumer P, Sumer M, Ozden B, Otan F 2007 Transmigration of mandibular canines: a report of six cases and a review of the literature. Journal of Contemporary Dental Practice 8: 104–110

Tarsitano J J, Wooten J W, Burditt J T 1971 Transmigration of nonerupted mandibular canines: report of cases. Journal of the American Dental Association 82: 1395–1397

Torres-Lagares D, Flores-Ruiz R, Infante-Cossio P, Garcia-Calderon M, Gutierres-Perez J L 2006 Transmigration of impacted lower canine. Case report and review of literature. Medicina Oral, Patologia Oral y Cirugia Bucal 11: 171–174

Yavuz M S, Aras M H, Büyükkurt M C, Tozoglu S 2007 Impacted mandibular canines. Journal of Contemporary Dental Practice 8: 78–85

Zvolanek J W 1986 Transmigration of an impacted mandibular canine. Illinois Dental Journal 55: 86–87